

Let's Talk About Palpation

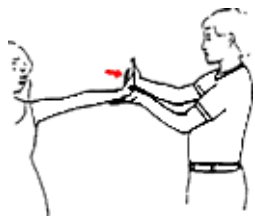
By Ben Benjamin, PhD

Question: True or false: Palpation is an excellent assessment method for locating injured structures.

Answer: False.

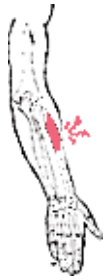Palpation is generally a poor and inaccurate method of locating injured structures.

Just finding tender areas in the body without the use of clinical testing procedures usually leads to confusion and inaccurate conclusions. Many individuals have tender spots throughout their entire bodies. Experienced therapists can find tender or painful areas on most people in dozens of places. Finding a tender area that verifies a practitioner's hunch about where an injury is located is easy to do, because so many structures are often tender when not injured. For instance, the occipital muscles may be tender or painful when palpated because of chronic muscle tension, not because the occipital muscles are injured.



Resisted extension of the wrist. Palpation can be an important verifying factor after anatomical testing procedures have discovered the injured tissue(s). Skilled touch can also help the practitioner more precisely locate the injured tissue, once the structure has been clearly identified. For example, if anatomical testing identifies an injured hamstring muscle tendon unit, a skilled practitioner can use palpation to locate the exact site of the damage along the muscle tendon unit.

Without first identifying the source of the pain, palpation may lead to inaccurate conclusions. For example, what appears to be a hamstring injury is frequently referred pain from a low back injury.



Extensor carpi radialis brevis tendon muscle unit with pain identified. To verify your assessment, it is generally important to compare tenderness on the right and left sides of the body, because the individual may be tender in many places as described above. If the individual is tender on the injured side and not tender on the uninjured side, this gives the practitioner a piece of corroborating evidence that the assessment is correct. On the other hand, if the uninjured side is just as tender as the injured side, the practitioner must look for further verification.

For example, the *extensor carpi radialis brevis* tendon (of tennis elbow fame) may be quite tender on palpation in many individuals, without being injured. But if resisted extension of the wrist is weak and painful at the lateral elbow on the right side, and resisted extension of the left wrist is strong and not painful, then tennis elbow on the right is very likely to be present, regardless of the tenderness on palpation.

Click [here](#) for more information about Ben Benjamin, PhD.



Page printed from:

http://www.massagetoday.com/archives/2001/02/10.html?no_b=true